

## SMALL CELL NEUROENDOCRINE CARCINOMA OF ETHMOID SINUS: CASE REPORT AND LITERATURE REVIEW

Forn-Chia Lin<sup>1</sup>, Li-Ching Lin<sup>1</sup>, Chang-Chuan Su<sup>2</sup>, Kuei-Li Lin<sup>1</sup>, Jenny Que<sup>1</sup>

*Department of Radiation Oncology<sup>1</sup>, Pathology<sup>2</sup>, Chi-Mei Foundation Hospital*

Malignant tumors arising in the paranasal sinuses account for 0.2 to 0.8% of all cancers. Squamous cell carcinoma is by far the most common malignant tumor. Primary small cell neuroendocrine carcinoma of ethmoid sinus is an uncommon and distinctive tumor with an aggressive clinical behavior. Besides, its morphological and immuno-histochemical features are similar to those of small cell carcinoma of lung. The need for a multi-disciplinary treatment approach combining surgery or radiotherapy and chemotherapy is indicated in treating these aggressive tumors.

We report a case of 40-year-old man who has small cell neuroendocrine carcinoma of ethmoid sinus with invasion of upper aspect of right maxillary sinus and medial aspect of right orbit. The patient was treated with surgery and adjuvant radiotherapy followed by systemic chemotherapy. Neither local recurrence nor distant metastasis was noted during follow-up of 6 months. The optimal treatment and the immuno-histo-chemical characteristics are discussed.

[ Therapeut Radiol Oncol 2003; 10(3): 175-179 ]

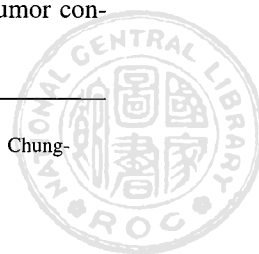
Key words: Small cell neuroendocrine carcinoma, Ethmoid sinus, Radiotherapy

### INTRODUCTION

Small cell neuroendocrine carcinoma of the paranasal sinuses was first described by Raychowdhuri in 1965 [10], drawing attention to the resemblance between the lesion and pulmonary small cell carcinoma. We report a case of small cell neuroendocrine carcinoma of ethmoid sinus with invasion of the upper medial aspect of right maxillary sinus and medial aspect of right orbit. The optimal treatment and the immuno-histo-chemical characteristics are discussed.

### CASE REPORT

A case of 40-year-old, previously healthy man who smoked a pack of cigarettes daily and drank alcohol on social occasion for 20 years, presented with a two-week history of diplopia, frequent epistaxis and nasal obstruction. Physical examination showed limited movement of right eye to medial aspect but the absence of neck lymphadenopathy. Local examination by an otolaryngologist showed a fleshy mass in the right nostril which was biopsied. Histological examination revealed a tumor con-



sisting of small-sized round to elongated cells with scanty cytoplasm and dark clumped chromatin (Fig. 1). Immuno-histo-chemical characteristics were demonstrated, including the presence of AE1/AE3, CD56, synaptophysin and NSE (neuron specific enolase) (Fig. 2), but the absence of chromogranin. Computed tomography revealed a mass in the ethmoid sinus with extension into the upper medial aspect of right maxillary sinus and medial aspect of right orbit (Fig. 3) but no enlarged lymph node over neck. The patient underwent partial maxillectomy and ethmoidectomy via Weber-Fuggerson approach and adjuvant radiotherapy with 50 Gy in 25

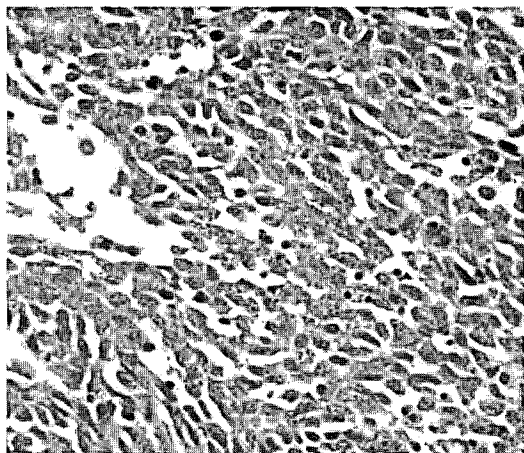


Fig 1. The individual tumor cells having round to oval nuclei, coarse chromatin and inconspicuous nucleoli.

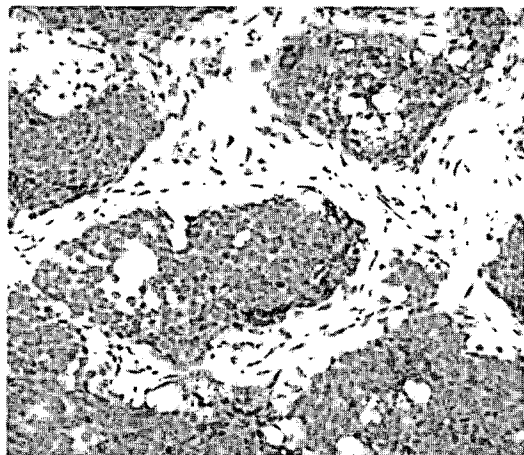


Fig 2. SNEC showing immuno-staining with NSE.

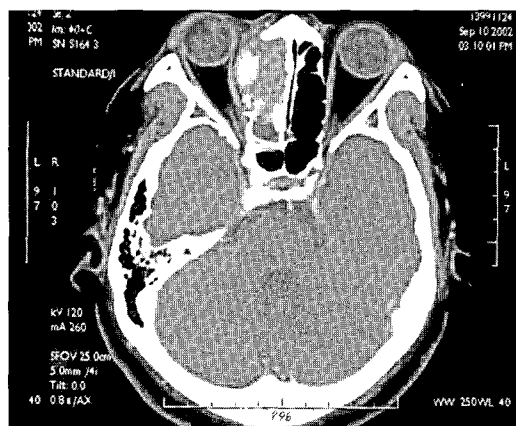



Fig 3. Computed tomography revealing a mass in the ethmoid sinus with extension into the medial aspect of right orbit.

fractions to tumor bed via 3-fields technique, followed by systemic chemotherapy of cyclophosphamide, vincristine and pharmorubicin. Neither local recurrence nor distant metastasis was noted during follow-up of 6 months.

## DISCUSSION

Malignant tumors arising in the paranasal sinuses account for 0.2 to 0.8% of all cancers. Squamous cell carcinoma is by far the most common malignant tumor, followed by adenocarcinoma, lymphoma, plasma cell tumor, malignant melanoma, esthesioneuroblastoma and sarcoma [9]. Primary small cell neuroendocrine carcinoma of ethmoid sinus is an uncommon and distinctive tumor with an aggressive clinical behavior. There appeared to be a sex predilection based on the primary site: most of the small cell neuroendocrine carcinoma of head and neck region were found in male subjects. A history of tobacco use was common, particularly in tumors that occurred in the head and neck region, but there was not as strong an association with smoking as there was with pulmonary small cell carcinoma [8].

Small cell neuroendocrine carcinoma is similar to those tumors in lung, composed of




small to intermediate-sized cells with a high nucleo/cytoplasmic ratio. Nuclei are round to oval and hyperchromatic, and contain dense or finely granular chromatin. The cytoplasm is scanty to moderate, has a pale eosinophilic or amphophilic quality and possesses poorly defined cell borders. The immuno-histo-chemical features of these tumors were investigated in some studies. In the report by Bayardo et al, the expression of neuroendocrine markers such as neuron specific enolase (NSE), synaptophysin and chromogranin, although positive in all cases, was variable and might be focally weak with individual markers. All of the cases showed strong diffuse staining for Cam 5.2 or AE1/AE3. S-100 and neurofilaments were negative in all cases [1].

The clinical features of small cell neuroendocrine carcinoma are nonspecific and similar to those of other sinonasal tumors [3]. Tumor may appear initially as a subcutaneous nodule in the inner canthus. The other common symptoms are epistaxis, diplopia, proptosis, pain and nasal obstruction. Paraneoplastic syndromes due to the ectopic production of adrenocorticotrophic hormone (ACTH) and antidiuretic hormone also occur. Kameya et al. reported increased levels of adrenocorticotrophic hormone (ACTH) and calcitonin in two of their patients [6] but the clinical evidence of endocrine overactivity was rarely detected. Extrapulmonary small cell neuroendocrine carcinomas can disseminate widely. Limited disease is defined as tumor confined to the organ of origin and the local regional nodes that are encompassable within a radiation portal. Tumors that have spread beyond one radiation portal are defined as extensive. In contrast to small cell lung cancer, most patients in whom an extrapulmonary primary site is identified have limited disease at the time of diagnosis. In a series of 71 patients from the Mayo Clinic, 76% of the tumors were localized at diagnosis [4]. However, invasion of adjacent structures is common and has been found in most cases

because the bony partitions between the nasal cavity, sinuses, orbit and cranial vault are quite thin and offer little resistance to cancer spread.

Extrapulmonary small cell neuroendocrine carcinoma is usually a fatal disease with a 13% 5-year survival rate [4]. In the study of extrapulmonary small cell carcinoma from Mayo Clinic, the median survival of fourteen patients with head and neck tumors was around 14 months [4]. The need for a multi-disciplinary treatment approach is indicated in treating these aggressive tumors. For most ethmoid sinus tumors, if they are resectable, surgery is usually performed first; post-operative irradiation is advised, even if resection margins are negative [5]. But for patients with locoregional small cell neuroendocrine carcinoma, the combination of chemotherapy and radiotherapy is a reasonable alternative to surgery [8]. Chemotherapy may well have a more prominent role in the management of the small cell neuroendocrine carcinoma whose morphological and immuno-histochemical features are similar to those of pulmonary small cell carcinoma. Despite the small numbers of cases reported and the various treatment modalities used, some suggestions regarding treatment options were made. Surgery or radiotherapy and adjuvant chemotherapy with a platinum-based regimen may be used with curative intent in patients with limited local disease. It is mandatory to use a platinum-based chemotherapeutic regimen for the control of systemic relapses. Twenty seven percent of the patients in the combined experience of Koss et al, Weiss et al and Bayardo et al. developed distant metastasis [7,11,1]. Galanis et al reported an 80% incidence of distant failure and a median time of relapse of 10 months for those patients with para-nasal tumors treated with surgery alone [4]. In the report of Bhattacharyya et al, the use of combined cisplatin and etoposide chemotherapy with proton radiation demonstrated initial success in treatment of these tumors [2]. This protocol had an accept-



able complication rate and conveyed less morbidity than craniofacial resection and conventional radiotherapy and further follow-up is required to determine the long-term success rate of this therapeutic protocol.

### CONCLUSION

Small cell neuroendocrine carcinoma of ethmoid sinus is rare. Few studies have reported some experience with malignant tumors in this location or other para-nasal sinuses. The best outcome was achieved by early diagnosis and by aggressive multi-disciplinary approach.

### REFERENCES

1. Bayardo PO, Salvatore MC, Andrew GH, Jatin PS: Small cell neuroendocrine carcinoma of the nasal cavity and paranasal sinuses. *Hum Pathol* 1998; 29: 826-832.
2. Bhattacharyya N, Thornton AF, Joseph MP, Goodman ML, Amrein PC: Successful treatment of esthesioneuroblastoma and neuroendocrine carcinoma with combined chemotherapy and proton radiation. *Arch Otolaryngol Head Neck Surg* 1997; 123: 34-40.
3. Chaudhry MR, Akhtar S, Kim DS: Neuroendocrine carcinoma of the ethmoid sinus. *Eur Arch Otorhinolaryngol* 1994; 251: 461-463.
4. Galanis E, Frytak S, Lloyd RV: Extrapulmonary small cell carcinoma. *Cancer* 1997; 79: 1729-1736.
5. James TP, William MM, Scott PS, Nicholas JC, Rodney RM: Nasal cavity and paranasal sinuses. In: Perez CA and Brady LW. eds. *Principles and Practice of Radiation Oncology*. 3rd ed. Philadelphia: Lippincott Co. 1997; 941-959.
6. Kameya T, Shimosato Y, Adachi I, et al.: Neuroendocrine carcinoma of the paranasal sinus: A morphological and endocrinological study. *Cancer* 1980; 45: 330-339.
7. Koss LG, Spiro RH, Hajdu S: Small cell carcinoma of minor salivary gland origin. *Cancer* 1972; 30: 737-741.
8. Murren J, Glastein EJ, Pass HI: Small cell lung cancer. In: DeVita VT, Hellman S, Rosenberg SA. eds. *Cancer: Principles and Practice of Oncology*. 6th ed. Philadelphia: Lippincott Co. 2001; 1010.
9. Osguthorpe JD: Sinus neoplasia. *Arch Otolaryngol Head Neck Surg* 1994; 120: 19-25.
10. Raychowdhuri RN: Oat cell carcinoma of paranasal sinuses. *J Laryngol Otol* 1965; 79: 253-255.
11. Weiss MD, deFries HO, Taxy JB et al.: Primary small cell carcinoma of the paranasal sinuses. *Arch Otolaryngol* 1983; 109: 341-343.



## 篩骨腔小細胞神經內分泌癌：病例報告及文獻回顧

林逢嘉<sup>1</sup> 林立青<sup>1</sup> 蘇正川<sup>2</sup> 林奎利<sup>1</sup> 郭珍妮<sup>1</sup>

奇美醫院 放射腫瘤科<sup>1</sup> 病理科<sup>2</sup>

副鼻竇腔惡性腫瘤佔人類所有惡性腫瘤的 0.2 到 0.8%，鱗狀細胞癌是最常見的組織型態，原發篩骨腔小細胞神經內分泌癌是一罕見且惡性之腫瘤，其組織型態及免疫化學染色特徵與肺小細胞癌相似；臨床上需併用手術或放射治療及化學治療等方式處理。

我們報告一位原發篩骨腔小細胞神經內分泌癌的病例，腫瘤侵犯至右眼窩內側及上顎鼻竇腔；於腫瘤摘除術後輔以放射治療及化學治療。追蹤至今約六個月，並無局部復發或遠端轉移情況發生。文中另探討小細胞神經內分泌癌之最適當處理模式及其免疫化學染色特徵。

[ 放射治療與腫瘤學 2003; 10(3): 175-179 ]

關鍵詞：小細胞神經內分泌癌，篩骨腔，放射治療

